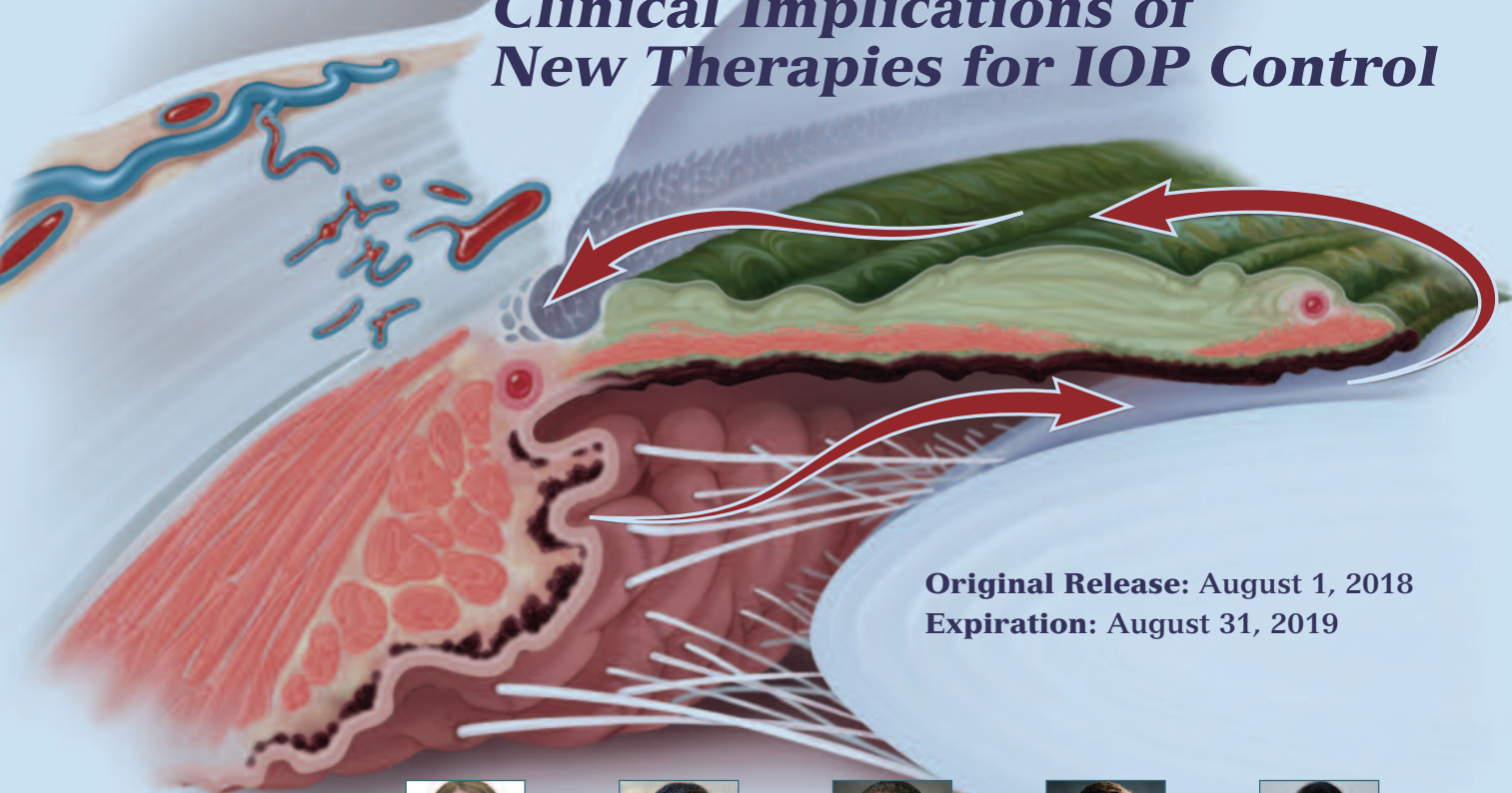


Visit <https://tinyurl.com/newglaucomatx> for online testing and instant CME certificate.

Changing the Course of Glaucoma

Clinical Implications of New Therapies for IOP Control




Original Release: August 1, 2018
Expiration: August 31, 2019

Faculty



Janet B. Serle, MD (Chair)



Jeffrey L. Goldberg, MD, PhD



Leon W. Herndon Jr, MD



Bennie Jeng, MD



Yvonne Ou, MD

This continuing medical education activity is jointly provided by New York Eye and Ear Infirmary of Mount Sinai and MedEdicus LLC.



This continuing medical education activity is supported through an unrestricted educational grant from Aerie Pharmaceuticals, Inc.

Distributed with EyeNet

PROGRAM CHAIR AND MODERATOR

Janet B. Serle, MD

Professor of Ophthalmology
Icahn School of Medicine at Mount Sinai
Director, Glaucoma Fellowships
The Mount Sinai Hospital
Mount Sinai Health System
New York, New York

FACULTY

Jeffrey L. Goldberg, MD, PhD

Professor and Chair of Ophthalmology
Byers Eye Institute
Stanford University
Palo Alto, California

Leon W. Herndon Jr, MD

Professor of Ophthalmology
Chief, Glaucoma Division
Duke Eye Center
Durham, North Carolina

Bennie Jeng, MD

Professor and Chair
Department of Ophthalmology &
Visual Sciences
University of Maryland School of Medicine
Baltimore, Maryland

Yvonne Ou, MD

Associate Professor of Ophthalmology
Chief, Glaucoma Service
University of California,
San Francisco School of Medicine
San Francisco, California

CME REVIEWER FOR NEW YORK EYE AND EAR INFIRMARY OF MOUNT SINAI

Kateki Vinod, MD

Assistant Professor of Ophthalmology
Icahn School of Medicine at Mount Sinai
Associate Adjunct Surgeon
New York Eye and Ear Infirmary of
Mount Sinai
New York, New York

Cover image reproduced with permission from
Alexandra Baker/Science Source.

This CME activity is copyrighted to MedEdicus LLC
©2018. All rights reserved.

LEARNING METHOD AND MEDIUM

This educational activity consists of a supplement and ten (10) study questions. The participant should, in order, read the learning objectives contained at the beginning of this supplement, read the supplement, answer all questions in the post test, and complete the Activity Evaluation/Credit Request form. To receive credit for this activity, please follow the instructions provided on the post test and Activity Evaluation/Credit Request form. This educational activity should take a maximum of 1.5 hours to complete.

ACTIVITY DESCRIPTION

Intraocular pressure (IOP) is determined by the balance between the rate of aqueous humor production and the rate at which it exits the eye. The primary source of outflow resistance in both healthy and glaucomatous eyes is the trabecular meshwork. In 2018, 2 glaucoma medications that directly target this source have entered the treatment armamentarium. This educational activity will evaluate the efficacy and safety data of these new treatment options and their potential role in the management of patients with glaucoma.

TARGET AUDIENCE

This educational activity is intended for US ophthalmologists, including glaucoma specialists.

LEARNING OBJECTIVES

Upon completion of this activity, participants will be better able to:

- Review the effects of glaucoma on the conventional outflow pathway
- Appraise the mechanisms of action of new drugs targeting relaxation of the trabecular meshwork and episcleral vasculature in patients with glaucoma
- Apply data from clinical trials of new drugs for lowering IOP

ACCREDITATION STATEMENT

This activity has been planned and implemented in accordance with the accreditation requirements and policies of the Accreditation Council for Continuing Medical Education (ACCME) through the joint providership of **New York Eye and Ear Infirmary of Mount Sinai** and **MedEdicus LLC**. The **New York Eye and Ear Infirmary of Mount Sinai** is accredited by the ACCME to provide continuing medical education for physicians.

In July 2013, the Accreditation Council for Continuing Medical Education (ACCME) awarded **New York Eye and Ear Infirmary of Mount Sinai** "Accreditation with Commendation," for six years as a provider of continuing medical education for physicians, the highest accreditation status awarded by the ACCME.

AMA CREDIT DESIGNATION STATEMENT

The **New York Eye and Ear Infirmary of Mount Sinai** designates this enduring material for a maximum of 1.5 AMA PRA Category 1 Credits™. Physicians should claim only the credit commensurate with the extent of their participation in the activity.

GRANTOR STATEMENT

This continuing medical education activity is supported through an unrestricted educational grant from **Aerie Pharmaceuticals, Inc.**

DISCLOSURE POLICY STATEMENT

It is the policy of **New York Eye and Ear Infirmary of Mount Sinai** that the faculty and anyone in a position to control activity content disclose any real or apparent conflicts of interest relating to the topics of this educational activity, and also disclose discussions of unlabeled/unapproved uses of drugs or devices during their presentation(s). **New York Eye and Ear Infirmary of Mount Sinai** has established policies in place that will identify and resolve all conflicts of interest prior to this educational activity. Full disclosure of faculty/planners and their commercial relationships, if any, follows.

DISCLOSURES

Jeffrey L. Goldberg, MD, PhD, had a financial agreement or affiliation during the past year with the following commercial interests in the form of *Consultant/Advisory Board*: **Aerie Pharmaceuticals, Inc**; **Allergan**; and **Bausch & Lomb Incorporated**.

Leon W. Herndon Jr, MD, had a financial agreement or affiliation during the past year with the following commercial interests in the form of *Consultant/Advisory Board*: **Aerie Pharmaceuticals, Inc**; **Alcon**; **Glaukos Corporation**; and **Sight**

Sciences; *Contracted Research*: **Glaukos Corporation**; *Honoraria from promotional, advertising or non-CME services received directly from commercial interests or their Agents (eg, Speakers Bureaus)*: **Glaukos Corporation**; and **New World Medical, Inc**; *Ownership Interest (Stock options, or other holdings, excluding diversified mutual funds)*: **Sight Sciences**.

Bennie Jeng, MD, had a financial agreement or affiliation during the past year with the following commercial interest in the form of *Consultant/Advisory Board*: **Aerie Pharmaceuticals, Inc**.

Yvonne Ou, MD, had a financial agreement or affiliation during the past year with the following commercial interest in the form of *Consultant/Advisory Board*: **Merck & Co, Inc**.

Janet B. Serle, MD, had a financial agreement or affiliation during the past year with the following commercial interests in the form of *Consultant/Advisory Board*: **Aerie Pharmaceuticals, Inc**; **Allergan**; **Auven Therapeutics**; **Bausch & Lomb Incorporated**; and **Pfizer Inc**; *Contracted Research*: **Allergan**; **Inotek Pharmaceuticals Corporation**; and **Ocular Therapeutix, Inc**; *Ownership Interest (Stock options, or other holdings, excluding diversified mutual funds)*: **Aerie Pharmaceuticals, Inc**.

NEW YORK EYE AND EAR INFIRMARY OF MOUNT SINAI PEER REVIEW DISCLOSURE

Kateki Vinod, MD, has no relevant commercial relationships to disclose.

EDITORIAL SUPPORT DISCLOSURES

Tony Realini, MD, had a financial agreement or affiliation during the past year with the following commercial interests in the form of *Consultant/Advisory Board*: **Aerie Pharmaceuticals, Inc**; **Inotek Pharmaceuticals Corporation**; **New World Medical, Inc**; and **Reichert, Inc**.

Diane McArdle, PhD; **Cynthia Tornallyay, RD, MBA, CHCP**; **Kimberly Corbin, CHCP**; **Barbara Aubel**; and **Michelle Ong** have no relevant commercial relationships to disclose.

DISCLOSURE ATTESTATION

The contributing physicians listed above have attested to the following:

- 1) that the relationships/affiliations noted will not bias or otherwise influence their involvement in this activity;
- 2) that practice recommendations given relevant to the companies with whom they have relationships/affiliations will be supported by the best available evidence or, absent evidence, will be consistent with generally accepted medical practice; and
- 3) that all reasonable clinical alternatives will be discussed when making practice recommendations.

OFF-LABEL DISCUSSION

This CME activity includes discussion of unlabeled and/or investigative uses of drugs. Please refer to the official prescribing information for each drug discussed in this activity for FDA-approved dosing, indications, and warnings.

NEW YORK EYE AND EAR INFIRMARY OF MOUNT SINAI PRIVACY & CONFIDENTIALITY POLICIES

<https://www.nyee.edu/health-professionals/cme/enduring-activities>

CME PROVIDER CONTACT INFORMATION

For questions about this activity, call 212-870-8127.

TO OBTAIN AMA PRA CATEGORY 1 CREDIT™

To obtain **AMA PRA Category 1 Credit™** for this activity, read the material in its entirety and consult referenced sources as necessary. Please take this post test and evaluation online by going to <https://tinyurl.com/newglaucomatx>. Upon passing, you will receive your certificate immediately. You must score 70% or higher to receive credit for this activity, and may take the test up to 2 times. Upon registering and successfully completing the post test, your certificate will be made available online and you can print it or file it.

DISCLAIMER

The views and opinions expressed in this educational activity are those of the faculty and do not necessarily represent the views of **New York Eye and Ear Infirmary of Mount Sinai**; **MedEdicus LLC**; **Aerie Pharmaceuticals, Inc**; **EyeNet**; or the **American Academy of Ophthalmology**.

Changing the Course of Glaucoma

Clinical Implications of New Therapies for IOP Control

INTRODUCTION

For the first time in more than 20 years, we have seen the approval of 2 new drugs with novel mechanisms of action for intraocular pressure (IOP) reduction in our patients with ocular hypertension and open-angle glaucoma. Both latanoprostene bunod—a nitric oxide (NO)-donating prostaglandin analogue—and netarsudil—a Rho kinase inhibitor—have their sites of action in the trabecular meshwork (TM), where resistance to aqueous humor outflow contributes to elevated IOP. Both drugs have been approved for first-line or adjunctive use. In this educational activity, the efficacy and safety data for each of these drugs will be reviewed and their potential roles in the management of patients with glaucoma will be discussed.

GLAUCOMA DAMAGE IN THE TRABECULAR OUTFLOW PATHWAY

In simplest terms, IOP is determined by the balance between the rate at which aqueous humor is produced by the ciliary epithelial cells and the rate at which it exits the eye through both the trabecular outflow pathway and the uveoscleral outflow pathway. There are no known causes of aqueous hypersecretion, which leaves impaired aqueous outflow as the cause of elevated IOP in eyes with glaucoma.

The primary source of outflow resistance in both healthy and glaucomatous eyes is the TM. Landmark research by Grant more than 50 years ago revealed that eyes with primary open-angle glaucoma and elevated IOP had increased resistance to outflow through the conventional (trabecular) outflow pathway, and this resistance was eliminated by surgical excision of the TM.^{1,2} The TM is a complex, multilayered tissue sandwiched between the anterior chamber proximally and Schlemm canal distally (Figure 1).³ The juxtacanalicular region of the TM, where the TM cells and cells from the inner wall of Schlemm canal interact, is primarily responsible for the outflow resistance that regulates IOP in healthy eyes and elevates IOP in glaucomatous eyes.¹

What changes in the TM cause a healthy eye to develop elevated IOP and become glaucomatous? Unlike many cells in the body, TM cells live a long time. Over time, they are subject to the cumulative stresses associated with normal metabolic activity, including both oxidative stress and exposure to cellular debris in the aqueous humor.⁴ These 2 processes are intertwined because chronic oxidative stress impairs the enzyme systems responsible for clearing cellular debris, leading to accumulation of oxidized debris in the outflow tract that can impair cellular functions such as IOP regulation, leading to reduced aqueous outflow.⁵

Over the 150-year history of glaucoma pharmacology, until recently, no medication has worked in the TM—the site of increased outflow resistance in glaucoma—to improve aqueous outflow. Miotics increase aqueous outflow, but their effect is indirect through action at the ciliary muscle to pull on the scleral spur and mechanically stretch the TM into a more open configuration.⁶ In 2018, 2 medications whose molecular mechanisms of action are directly on the TM cells to improve aqueous humor outflow have entered the treatment armamentarium.

MECHANISMS AND SITES OF ACTION FOR GLAUCOMA MEDICATIONS

With their ability to improve trabecular outflow, latanoprostene bunod and netarsudil—both approved by the US Food and Drug Administration in late 2017—have returned to the roots of glaucoma pharmacology, that is, to 1867, when Sir Thomas Fraser introduced the first IOP-lowering medication, the calabar bean, and its key active ingredient, the potent miotic physostigmine.⁷

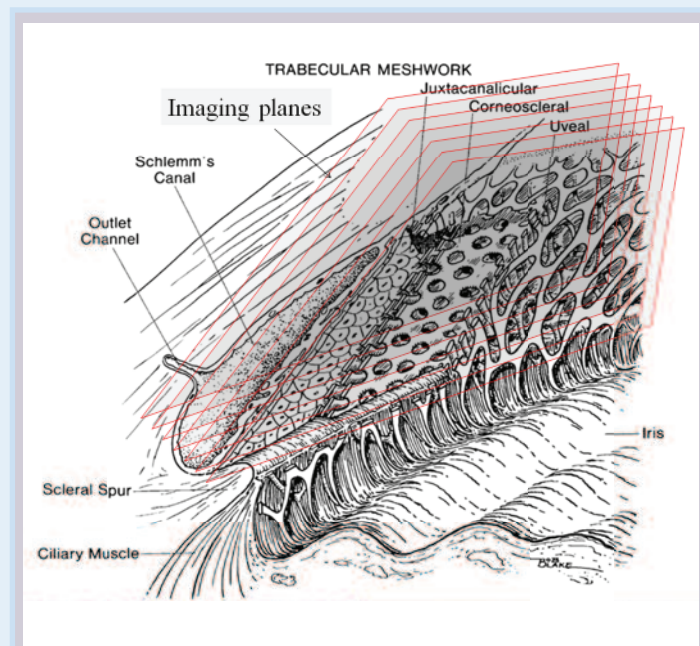


Figure 1. Schematic anatomy of the trabecular outflow pathway

Reprinted with permission from Park CY, Lee JK, Kahook MY, Schultz JS, Zhang C, Chuck RS. Revisiting ciliary muscle tendons and their connections with the trabecular meshwork by two photon excitation microscopic imaging. *Invest Ophthalmol Vis Sci*. 2016;57(3):1096-1105. The Association for Research in Vision and Ophthalmology Copyright © 2018. All rights reserved.

Table 1. Glaucoma Medications and Their Mechanisms of Action⁶

Class	Drugs	Mechanism of Action
Prostaglandin analogues	Latanoprost, travoprost, bimatoprost, tafluprost	Increase uveoscleral outflow
Nitric oxide–donating prostaglandin analogue	Latanoprostene bunod	Increases uveoscleral outflow; increases trabecular outflow
Rho kinase inhibitor	Netarsudil	Increases trabecular outflow; decreases episcleral venous pressure; decreases aqueous humor production
Beta blockers	Timolol, betaxolol, carteolol, metipranolol, levobunolol	Decrease aqueous humor production
Carbonic anhydrase inhibitors	Topical: dorzolamide, brinzolamide Systemic: acetazolamide, methazolamide	Decrease aqueous humor production
Adrenergic agonists	Brimonidine, apraclonidine	Decrease aqueous humor production; increase uveoscleral outflow
Miotics	Pilocarpine, carbachol, physostigmine, echothiophate	Increase trabecular outflow
Hyperosmotics	Mannitol, glycerin, isosorbide	Vitreous humor decompression; decrease aqueous humor production
Fixed combinations	Carbonic anhydrase inhibitor/beta blocker, adrenergic agonist/beta blocker, carbonic anhydrase inhibitor/adrenergic agonist	Vary according to components

Note: Table reflects drugs available in the United States.

Efficacy and Safety of New Aqueous Humor Outflow Drugs

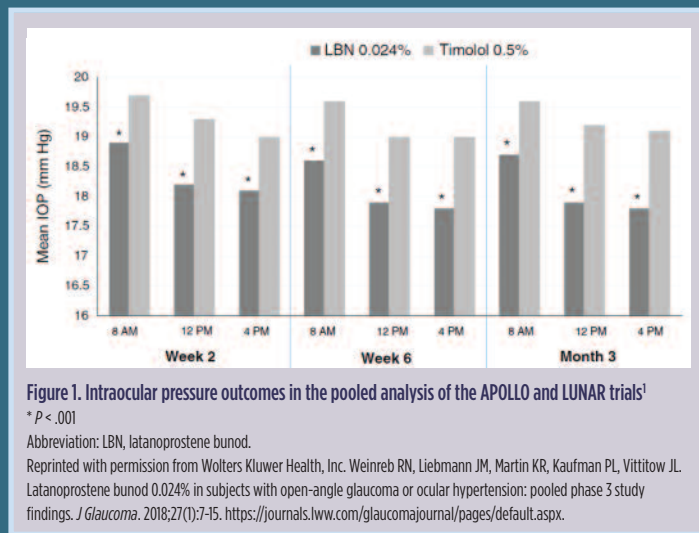
LATANOPROSTENE BUNOD

The efficacy and safety of latanoprostene bunod were compared with those of timolol in 2 phase 3 clinical trials: APOLLO and LUNAR. In a pooled analysis of these 2 studies, mean intraocular pressure (IOP) was reduced from 26.7 mm Hg to 17.8 to 18.9 mm Hg across the 9 on-treatment time points of 8 AM, 12 PM, and 4 PM at weeks 2, 6, and 12 in the latanoprostene bunod group, and from 26.5 mm Hg to 19.0 to 19.7 mm Hg in the timolol group ($P < .001$ at all time points; **Figure 1**).¹ In addition, significantly more patients in the latanoprostene bunod group than in the timolol group achieved IOP ≤ 18 mm Hg at all time points (20.1% vs 11.2%; $P = .001$) and achieved IOP reductions of $\geq 25\%$ at all time points (32.9% vs 19.0%; $P < .001$). The most common side effects in the latanoprostene bunod group were conjunctival/ocular hyperemia (5.9%/2.0%) and eye irritation/pain (4.6%/3.6%).

Additionally, a phase 2 study comparing latanoprostene bunod, 0.024%, with latanoprost, 0.005%, demonstrated a 1.23-mm Hg greater IOP reduction with latanoprostene bunod than with latanoprost after 28 days of dosing.²

NETARSUDIL

The efficacy and safety of netarsudil were compared with timolol in 2 phase 3 clinical trials: ROCKET-1 and ROCKET-2 (Rho Kinase Elevated IOP Treatment Trial 1 and Trial 2). The ROCKET-1 study analyzed eyes with a baseline IOP of < 27 mm Hg, and the ROCKET-2 study analyzed eyes with a baseline IOP of < 25 mm Hg.³ In ROCKET-1, netarsudil lowered IOP by 3.3 to 5.0 mm Hg across the study's 9 on-treatment time points (8 AM, 10 AM, and 4 PM at weeks 2, 6, and 12; **Figure 2**), whereas timolol lowered IOP by 3.7 to 5.1 mm Hg across the same time points. The study was designed as a noninferiority



trial, and netarsudil did not meet the threshold for noninferiority to timolol in the primary analysis of patients with a baseline IOP of < 27 mm Hg, but did meet the criteria for noninferiority to timolol in a secondary analysis of patients with a baseline IOP of < 25 mm Hg. In ROCKET-2, mean IOP reductions were 3.3 to 4.6 mm Hg for once-daily netarsudil, 4.1 to 5.4 mm Hg for twice-daily netarsudil, and 3.7 to 5.1 mm Hg for timolol. In this study, once-daily and twice-daily netarsudil did meet the threshold for noninferiority to timolol in the primary analysis of patients with IOP of < 25 mm Hg (**Figure 2**). The twice-daily dosing was not as well tolerated as the once-daily dosing; thus, once-daily dosing is the US Food and Drug Administration–approved and recommended treatment regimen. In addition, the ROCKET-4 trial demonstrated noninferiority to timolol in patients with an IOP of up to < 30 mm Hg.⁴

RHO KINASE INHIBITOR

Netarsudil inhibits the enzyme Rho kinase and the norepinephrine transporter (Figure 2; Table 1).⁹ In vivo human and animal studies demonstrated that the primary mechanism of netarsudil to lower IOP is enhanced trabecular outflow.^{9,10} The secondary mechanism is reduced episcleral venous pressure.¹⁰ Additionally, the drug might have a small effect (reduction) on aqueous humor inflow.^{9,10} A fixed-dose combination of netarsudil and latanoprost is in clinical trials.¹¹

FACULTY DISCUSSION

Clinical Significance of Mechanism of Action

Dr Serle: Latanoprostene bunod and netarsudil have been approved for IOP reduction in eyes with ocular hypertension or primary open-angle glaucoma for both first-line and adjunctive use (see Sidebar: Efficacy and Safety of New Aqueous Humor Outflow Drugs). They each have a novel mechanism of action, and both work directly in the TM. What is the practical significance of these drugs and their mechanisms of action?

Dr Herndon: These drugs have mechanisms of action that are complementary to the drugs we already use. I am very interested in trying them in combination with our current treatment options.

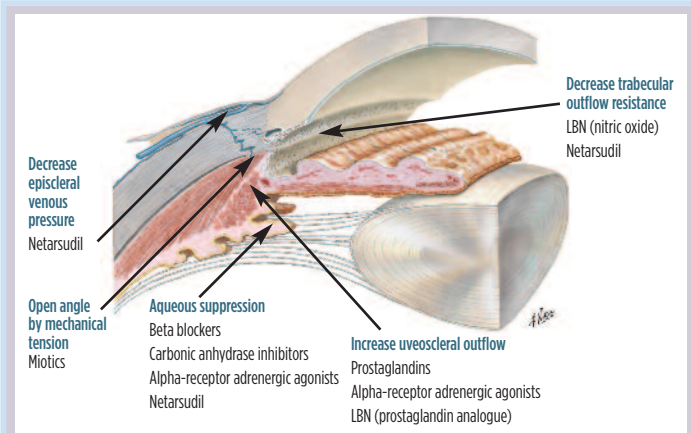


Figure 2. Sites of action of glaucoma medications

Abbreviation: LBN, latanoprostene bunod.

Netter illustration used with permission of Elsevier, Inc. All rights reserved. www.netterimages.com.

NITRIC OXIDE–DONATING PROSTAGLANDIN ANALOGUE

Latanoprostene bunod is the only drug in this novel class. The molecule dissociates into latanoprost and NO, each of which has distinct actions within the eye. Latanoprost increases uveoscleral outflow. Studies in human TM cells suggest NO mediates trabecular relaxation and increases trabecular outflow (Figure 2; Table 1).^{6,8}

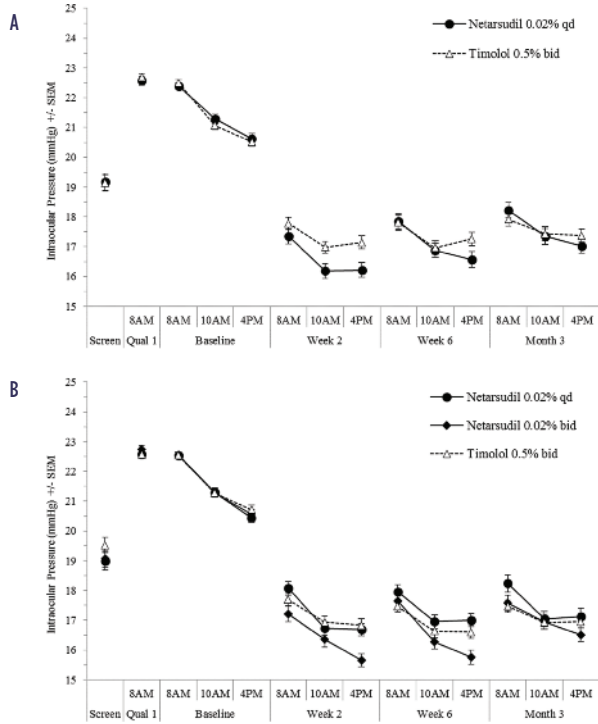


Figure 2. Intraocular pressure outcomes of the secondary analysis of ROCKET-1 (Rho Kinase Elevated IOP Treatment Trial 1) (A) and primary analysis of ROCKET-2 (Rho Kinase Elevated IOP Treatment Trial 2) (B) in patients with a baseline intraocular pressure of < 25 mm Hg³

Reprinted from *American Journal of Ophthalmology*, 186, Serle JB, Katz LJ, McLaurin E, et al; ROCKET-1 and ROCKET-2 Study Groups; Two phase 3 clinical trials comparing the safety and efficacy of netarsudil to timolol in patients with elevated intraocular pressure: Rho Kinase Elevated IOP Treatment Trial 1 and 2 (ROCKET-1 and ROCKET-2), 116-127, Copyright 2018, with permission from Elsevier.

Common side effects of once-daily netarsudil were typically graded as mild and included conjunctival hyperemia (50.2%), conjunctival hemorrhage (14.7%), corneal deposits (8.8%), and blurred vision (7.2%), all of which were statistically more common than with timolol.³

Netarsudil is also being evaluated in a fixed-dose combination with latanoprost. In a 12-month phase 3 study, MERCURY-1, the netarsudil/latanoprost fixed-dose combination met the primary efficacy end point, with superiority over the individual components latanoprost and netarsudil at 3 months, and provided 1 to 3 mm Hg greater IOP reductions over the individual components at all time points ($P < .0001$).⁵ The efficacy data was maintained at the 12-month time point.⁶

REFERENCES

- Weinreb RN, Liebmann JM, Martin KR, Kaufman PL, Vittitow JL. Latanoprostene bunod 0.024% in subjects with open-angle glaucoma or ocular hypertension: pooled phase 3 study findings. *J Glaucoma*. 2018;27(1):7-15.
- Weinreb RN, Ong T, Scassellati Sforzolini B, Vittitow JL, Singh K, Kaufman PL; VOYAGER Study Group. A randomised, controlled comparison of latanoprostene bunod and latanoprost 0.005% in the treatment of ocular hypertension and open angle glaucoma: the VOYAGER study. *Br J Ophthalmol*. 2015;99(6):738-745.
- Serle JB, Katz LJ, McLaurin E, et al; ROCKET-1 and ROCKET-2 Study Groups. Two phase 3 clinical trials comparing the safety and efficacy of netarsudil to timolol in patients with elevated intraocular pressure: Rho Kinase Elevated IOP Treatment Trial 1 and 2 (ROCKET-1 and ROCKET-2). *Am J Ophthalmol*. 2018;186:116-127.
- US Food and Drug Administration. *Dermatologic and Ophthalmic Drugs Advisory Committee Meeting Briefing Document*. Silver Spring, MD: US Food and Drug Administration; October 13, 2017. NDA 208254.
- Asrani S, Heah TGH, Kocpzyński C. A 3-month interim report of a prospective, double-masked, randomized, multi-center, active-controlled, parallel-group 12-month study assessing the safety and ocular hypotensive efficacy of Pg524 ophthalmic solution. Paper presented at: 2017 American Glaucoma Society Annual Meeting; March 2-5, 2017; Coronado, CA.
- Brubaker J, Teymoorian S, Lewis RA, et al. Once-daily fixed-dose combination of netarsudil 0.02% and latanoprost 0.005% in ocular hypertension/open-angle glaucoma: 12-month data from MERCURY-1. Paper presented at: 2018 American Glaucoma Society Annual Meeting; March 1-4, New York, NY.

Dr Goldberg: Having drugs with novel mechanisms of action gives us expanded options for medical therapy before moving to more invasive means of IOP reduction.

Dr Ou: It is remarkable that we have come this far without a medication that directly targets the diseased tissue in the trabecular outflow pathway. I am also intrigued that these drugs have not 1, but multiple mechanisms of action.

Dr Serle: What are the mechanisms by which latanoprostene bunod lowers IOP?

Dr Herndon: Latanoprostene bunod dissociates into latanoprost—with which we are all familiar—and NO. Latanoprost lowers IOP by enhancing aqueous egress from the eye via the uveoscleral outflow pathway. Nitric oxide presumably lowers IOP by relaxing TM cells, which increases aqueous egress through the trabecular pathway as well.⁸ However, there are no human or animal trial data to substantiate this assumption. Also, the concentration of latanoprost in the commercially available latanoprostene bunod formulation is approximately 5-fold higher than that of ordinary latanoprost. Although this might also be thought to account for some of the difference in IOP reduction seen between latanoprost and latanoprostene bunod,^{12,13} a dose-response study of latanoprost suggested that the 0.005% concentration was maximally effective, so the additional IOP reduction may be a function of the NO moiety.¹⁴ Also, an NO effect on IOP is also likely because latanoprostene bunod lowers IOP in mice that have had the prostaglandin F_{2α} receptor gene knocked out, thus blocking any latanoprost effect.¹⁵ The effects on ocular penetration and bioavailability of adding the NO moiety onto latanoprostene bunod, however, remain unknown, and further work is required to clarify the extent and exact mechanism.

Dr Serle: What are the mechanisms of action of netarsudil?

Dr Goldberg: Netarsudil is particularly interesting, not just because of its activity in the TM, but because its molecular activity is profoundly different from that of the other agents we are using now. It might have multiple molecular mechanistic effects on TM cells and other cells throughout the anterior segment that might prove complementary to the therapeutics we are otherwise using. At the TM, Rho kinase inhibition might increase outflow by relaxing TM cells and changing the cell/cell and cell/matrix interactions.¹⁶ This raises the possibility that netarsudil—and the NO moiety of latanoprostene bunod—not only lowers IOP, but also might be disease modifying in the aging TM. In the scientific preclinical literature, Rho kinase inhibition has also been shown to enhance cellular survival.¹⁷ One of the fundamental mechanisms for TM aging and increased IOP associated with glaucoma has been related to the survival of the TM cells.⁴ These preclinical observations remain to be explored in human studies, but the premise of the Rho kinase inhibition pathway complementing our current glaucoma management strategies is promising.

Dr Herndon: In addition to its activity in the TM, netarsudil acts on the episcleral veins to lower episcleral venous pressure.^{10,18} This is often considered the source of the floor effect in medical glaucoma therapy. Medications typically do not lower IOP below the level of episcleral venous pressure. If we could lower

episcleral venous pressure, lower target IOP might be achievable with medical therapy.

Dr Serle: In addition, there is evidence that netarsudil suppresses the production of aqueous humor through its norepinephrine transport activity.⁹ To date, however, this has been demonstrated only in animal models.⁹ How are these drugs labeled for use?

Dr Herndon: Both latanoprostene bunod and netarsudil are indicated for the reduction of IOP in eyes with primary open-angle glaucoma or ocular hypertension. There are no restrictions in primary vs adjunctive use, so both are potentially first-line agents.

Dr Serle: How important is once-daily dosing, which these 2 drugs have in common?

Dr Ou: Once-daily dosing is essential if we are going to use these drugs first-line. The prostaglandins have set the bar quite high for dosing convenience. As for adjunctive use, once-daily dosing offers a significant advantage over other common adjunctive agents, such as brimonidine and the carbonic anhydrase inhibitors.

Safety of Latanoprostene Bunod and Netarsudil

Dr Serle: Safety is an important feature of all glaucoma medications. How do the safety profiles of these drugs compare with those of other available drugs?

Dr Goldberg: One advantage to both of these new drugs is the general lack of systemic side effects. Because these 2 new drugs do not have significant systemic side effects, their place in my treatment pattern will be as early adjuncts.

Dr Serle: What about their ocular safety profiles?

Dr Ou: With latanoprostene bunod, we have the potential for side effects arising from both the latanoprost moiety and the NO moiety. We are very familiar with the side effects of the prostaglandin drug class; the most common side effects in the trials were hyperemia, lash growth, and iris color changes.¹⁹ The additional side effect associated with latanoprostene bunod is pain upon instillation, which was reported by approximately 2% of patients in phase 3 studies.²⁰ Netarsudil is a new entity, but the most common side effect is one with which we are familiar—hyperemia at 50.2%, which was graded as mild.²¹

Dr Serle: When the prostaglandins first appeared, we had to learn a great deal about new side effects, such as eyelash growth and iris color changes. We had to learn that these were cosmetic issues and were not generally visually significant. We also had to learn how to talk to patients about these concerns. Netarsudil has a number of side effects that are new to us: conjunctival hemorrhages and corneal verticillata. What is the significance of these findings, and how do we talk to patients about them?

Dr Ou: The hemorrhages associated with netarsudil were first noted in the clinical trials. These were small, petechial microhemorrhages typically located right along the limbus. They were seen in 13% to 15% of eyes in the once-daily netarsudil dosing groups in the phase 3 ROCKET-1 and

Corneal Verticillata From the Cornea Specialist's Perspective

Bennie Jeng, MD

Both cationic (positively charged) and amphiphilic (soluble in both aqueous and lipid) drugs are known to cause phospholipidosis, that is, the accumulation of phospholipids in lysosomes within corneal epithelial cells.¹ Clinically, this manifests as corneal verticillata or a whorl-like pattern of gray or golden deposits in the basal epithelium of the cornea. This appearance is most frequently attributed to Fabry disease or the use of amiodarone, a commonly used antiarrhythmic medication.² Other drugs that less commonly cause corneal verticillata include chloroquine, hydroxychloroquine, chlorpromazine, tamoxifen, and even various nonsteroidal anti-inflammatory drugs, such as ibuprofen, naproxen, and indomethacin.¹ Although there are reports of corneal verticillata causing glare or decreased vision,³ this finding is typically incidental, and corneal verticillata does not cause any visual symptoms for the patient, even if the corneal findings are central in location.

Netarsudil is both cationic and amphiphilic, and, therefore, as can be expected, it can cause phospholipidosis, resulting in corneal verticillata. It is possible that netarsudil could be additive in the development of corneal verticillata in a patient receiving amiodarone, but it would not be expected to cause more symptoms. However, given that even long-standing corneal verticillata can be reversed upon cessation of the causative drug, discontinuing the drug simply on the basis of the presence of corneal verticillata is not indicated.¹

Corneal verticillata does not generally cause symptoms for the patient, and it is not expected to cause any disturbances with the surgeon's view during cataract surgery. In addition, the presence of corneal verticillata will not affect preoperative biometric measurements. As such, discontinuing the drug prior to cataract surgery is not indicated. This is illustrated in the following case.

CASE

A 74-year-old male with a history of ventricular fibrillation presented for evaluation of progressively decreasing vision in both eyes, with some symptoms of glare when driving at night. Pertinent medications included amiodarone 400 mg once daily by mouth, which he had been taking for the past 8 years. Best spectacle corrected visual acuity was 20/50 OD and 20/40 OS. Brightness acuity testing decreased vision to the level of 20/200 in both eyes. Slit-lamp examination was notable for gold-colored vortex keratopathy, most prominent in the inferior interpalpebral zone from limbus to limbus, but also extending superiorly into the entrance pupil. A 2 to 3+ nuclear sclerotic cataract was noted in both eyes, and the posterior segment examination was within normal limits. Corneal topography was performed, demonstrating less than 1 diopter of regular-appearing with-the-rule astigmatism in both eyes. Ophthalmic biometry was performed without difficulty. The patient consented to phacoemulsification cataract surgery with intraocular lens implantation in the right eye first and then the left eye in 2 weeks.

During the cataract surgery, there was no difficulty with visualization of the lens capsule for capsulorhexis, nor was there disruption of the view by the corneal epithelial changes for any other part of the cataract surgery. Postoperatively, the patient's uncorrected visual acuity measured 20/20 in both eyes, with elimination of any glare symptoms.

This case illustrates that the corneal epithelial changes due to the use of amiodarone did not compromise the view needed to perform uncomplicated phacoemulsification cataract surgery. In addition, the epithelial changes did not affect the ability to obtain accurate biometry, and the glare—which resolved after cataract surgery—was attributable to the lens opacity and not the corneal findings.

REFERENCES

1. Raizman MB, Hamrah P, Holland EJ, et al. Drug-induced corneal epithelial changes. *Surv Ophthalmol*. 2017;62(3):286-301.
2. Falke K, Büttner A, Schittkowski M, et al. The microstructure of cornea verticillata in Fabry disease and amiodarone-induced keratopathy: a confocal laser-scanning microscopy study. *Graefes Arch Clin Exp Ophthalmol*. 2009;247(4):523-534.
3. Dovie JM, Gurwood AS. Acute onset of halos and glare: bilateral corneal epithelial edema with cystic eruptions – atypical presentation of amiodarone keratopathy. *Optometry*. 2006;77(2):76-81.

ROCKET-2 trials.²¹ They resolved spontaneously within 1 to 3 weeks. Their cause and significance are unknown.

Dr Goldberg: Corneal verticillata was reported in approximately 5% to 9% of patients receiving once-daily netarsudil in the phase 3 ROCKET-1 and ROCKET-2 trials (see **Sidebar: Corneal Verticillata From the Cornea Specialist's Perspective**).²¹ They typically appeared within the first 6 to 13 weeks of dosing, and upon discontinuation of the drug, they resolved within weeks to months. In no case did they affect visual acuity, and patients were not aware of them; they were strictly a physician-noted phenomenon.

Dr Serle: Additionally, in patients with corneal verticillata, visual function measured with the Visual Function Index and contrast sensitivity were not affected.²²

Incorporating New Drugs Into Clinical Use

Dr Serle: Where will these 2 new outflow drugs fit into your treatment scheme?

Dr Ou: Currently, I start with a prostaglandin, and my preferred first adjunct is a beta blocker, primarily because of the once-daily dosing convenience. The new drugs offer alternatives to this approach. Now if I need additional reduction in IOP, I can switch




Figure 3. Visual fields (A) and optical coherence tomography images (B) of the patient presented in Case 1

Images courtesy of Leon W. Herndon Jr, MD

from a prostaglandin to latanoprostene bunod or I can add netarsudil. This allows me to avoid the side effects of beta blockers while maintaining the once-daily dosing convenience.

Dr Serle: I agree that once-daily dosing and the lack of systemic side effects position these drugs as excellent choices for both primary and adjunctive use.

Dr Goldberg: Netarsudil might also have an additional property that would make it useful in some patients, that is, those who might benefit from neuroprotection. The Rho kinase pathway has been implicated in neuroprotection for 15 years and has been comprehensively reviewed recently.¹⁶ We reported a study evaluating the neuroprotective activity of topical netarsudil in a rat model of traumatic optic nerve injury.¹⁷ In this model, the topical administration of netarsudil promoted survival of retinal ganglion cells and regeneration of their axons significantly more so than did placebo. These findings are very preliminary and have no direct application in humans so far. That said, the data are certainly consistent with the body of literature showing Rho kinase inhibition is neuroprotective and, in fact, promotes survival and regeneration. With these preclinical data in mind, I would be very motivated to use netarsudil adjunctively in certain patients, such as those with normal-tension glaucoma or those with primary open-angle glaucoma who are progressing despite having a low IOP. We might be able to lower IOP acutely and, in the longer term, monitor visual fields closely for changes in visual function.

CASE 1

From the Files of Leon W. Herndon Jr, MD

A 77-year-old African American male was referred for a second opinion on possible borderline open-angle glaucoma. He has a history of ocular surface disease and his highest recorded IOPs were in the low 20s. His best corrected visual acuity was 20/30 OD and 20/20 OS. His IOP was 33 mm Hg OD and 17 mm Hg OS while using timolol once daily in the morning. He had mild-to-moderate cataracts in both eyes. His corneas were thin, and his corneal hysteresis was low. He had open angles. His optic nerves were large, with large cups but intact rims. His visual fields were essentially full in both eyes (**Figure 3A**). Optical coherence tomography (OCT) of his retinal nerve fiber layer (RNFL) was essentially normal, but he did have some thinning of the macula inferiorly (**Figure 3B**).

Dr Serle: His visual fields and RNFL OCT are essentially normal. Is this glaucoma?

Dr Herndon: I think he has glaucoma based partly on his IOP and partly on his macular OCT. The role of the macular OCT in glaucoma has been garnering more attention in recent years. In his case, there is intereye asymmetry, with the right eye being thinner in the inferior region.

Dr Goldberg: In early glaucoma, structural testing with OCT is likely more sensitive than functional testing with perimetry to detect abnormalities. There is mounting evidence that macular thinning on OCT, particularly in the ganglion cell layer, is an early finding in glaucoma that can identify the disease, even when the field is still intact.²³⁻²⁵ So often in the early stages, combining RNFL OCT with a macular ganglion cell complex OCT can add further data to help decide if a glaucoma suspect actually has early glaucoma.

Dr Herndon: This patient's corneal hysteresis was also low in the right eye. Hysteresis is a measure of the deformability of the cornea and is likely a better measure of corneal biomechanical properties than corneal thickness. Studies have demonstrated that glaucomatous eyes have lower hysteresis compared with healthy eyes,^{26,27} and hysteresis has also been associated with the risk of glaucoma progression.^{28,29}

Dr Ou: He has many risk factors for glaucoma and likely has early glaucoma. What target IOP did you select?

Dr Herndon: His IOP on our first encounter was 33 mm Hg in the right eye, but his referral records showed IOPs that were consistently in the mid-20s with timolol. Assuming our 33 mm Hg was an outlier, I aimed for a target IOP in the high teens—a 25% to 30% reduction from his current level.

Dr Serle: What treatment options might reasonably achieve this IOP?

Dr Ou: The easiest option would be to switch from timolol to a prostaglandin analogue. He is already accustomed to taking drops. Selective laser trabeculoplasty would be a reasonable step as well. It lowers IOP as well as a prostaglandin does^{30,31} and is highly effective as a replacement for medications.^{32,33}

Dr Goldberg: Given his age and stage of disease, we have the luxury of erring on the side of safety over efficacy in this patient. We do not need to be overly aggressive in lowering his IOP. I would likely switch to a prostaglandin, but if he had any issues with tolerance or adherence, selective laser trabeculoplasty (SLT) would be a reasonable alternative to medical therapy.

Dr Serle: Netarsudil can also be considered as a first-line treatment option in this patient because it is dosed once daily, well tolerated, and efficacious. As part of a different class of medications, it could be efficacious in patients in whom other commonly used agents have been ineffective.

Dr Herndon: I switched him from timolol to latanoprost, which did not achieve target IOP. I performed SLT, which also failed to achieve target IOP.

Dr Serle: Are there other options?

Dr Goldberg: At this point, options could include switching to latanoprostene bunod, with the goal of getting a little extra IOP reduction, or adding a second medication to the latanoprost. I might add brimonidine, a carbonic anhydrase inhibitor, or netarsudil.

Dr Ou: Because the patient has failed latanoprost, he might not be able to achieve a 25% to 35% IOP reduction by just switching to latanoprostene bunod. I would favor adding netarsudil instead, given its distinct mechanisms of action. If it works to achieve target IOP alongside his latanoprost, it will be interesting to see if the fixed-dose combination works, which would reduce his number of medications from 2 to 1.

Dr Serle: SLT was ineffective and latanoprost alone did not reduce the IOP in this patient. Thus, the next step would be to add a second agent. The current options for a most simplified medical regimen with minimum systemic side effects are substituting latanoprostene bunod for latanoprost or adding netarsudil to latanoprost.

Latanoprostene bunod has been shown to reduce IOP approximately 1 to 1.5 mm Hg more than latanoprost alone,³⁴ and netarsudil used in combination with latanoprost reduces IOP by an additional 2 to 3 mm Hg.¹¹ Patients have individual responses to medications, and agents might be more or less effective than the average IOP reductions reported in clinical trials. Thus, a regimen must be tried and evaluated for efficacy and side effects to determine if it “fits.”

Dr Serle: Would you consider a surgical option?

Dr Herndon: The cataract in his right eye is becoming visually significant. Cataract surgery alone can provide substantial and sustained reductions in IOP. A recent meta-analysis estimated that at 6, 12, 24, and 36 months after cataract surgery, mean IOP is reduced by 12%, 14%, 15%, and 9%, respectively, and the mean number of IOP-lowering medications is reduced by 0.6, 0.5, 0.4, and 0.2, respectively.³⁵ If we want additional IOP reduction, we could add minimally invasive glaucoma surgery at the time of cataract surgery.

CASE 2

From the Files of Yvonne Ou, MD

A 61-year-old female with a 2-year history of primary open-angle glaucoma recently transferred her care. She had no family history of glaucoma but did have high myopia. Her IOP, now treated with maximal medical therapy, was in the range of 10 to 17 mm Hg in both eyes. A review of her visual fields showed recent progression in this range. Her angles were open, her corneal thickness was average in both eyes, and she had mild cataracts in both eyes. Of note, she had epithelial dysplasia in the inferior cornea of her left eye. Her optic nerves had peripapillary atrophy consistent with her myopia. Her right nerve had a larger cup and an inferior notch, whereas her left nerve had some inferotemporal thinning (**Figure 4A**). RNFL OCT revealed generalized thinning in both eyes, more so in the right eye than in the left eye (**Figure 4C**). Her macular OCT demonstrated inferior thinning in both eyes (**Figure 4D**). Her visual fields revealed both superior and inferior arcuate defects encroaching on fixation in both eyes, again with the right eye having greater overall field loss (**Figure 4B**). SLT was performed in the right eye, but there was no significant IOP response. We proceeded with trabeculectomy with mitomycin C in the right eye just a few months ago. She is doing well postoperatively, with IOP in the range of 7 to 10 mm Hg on no medications. The IOP in her left eye has varied between 16 and 23 mm Hg while still on maximal medical therapy, which consists of a prostaglandin, a beta blocker, and the brinzolamide/brimonidine fixed combination. The visual field in her left eye continues to progress.

Dr Serle: The right eye is currently under excellent control postsurgery. You mentioned a region of epithelial dysplasia in the left cornea. Is that a factor in her glaucoma treatment?

Dr Ou: Upon workup, this region turned out to be squamous CIN (conjunctival intraepithelial neoplasia). Therapy was initiated with interferon- 2β and is now being treated with 5-fluorouracil.

Dr Serle: This has implications for her glaucoma therapy.

Dr Ou: It does. I considered SLT, but the lack of response in her right eye suggests it will not be helpful.³⁶ I also considered

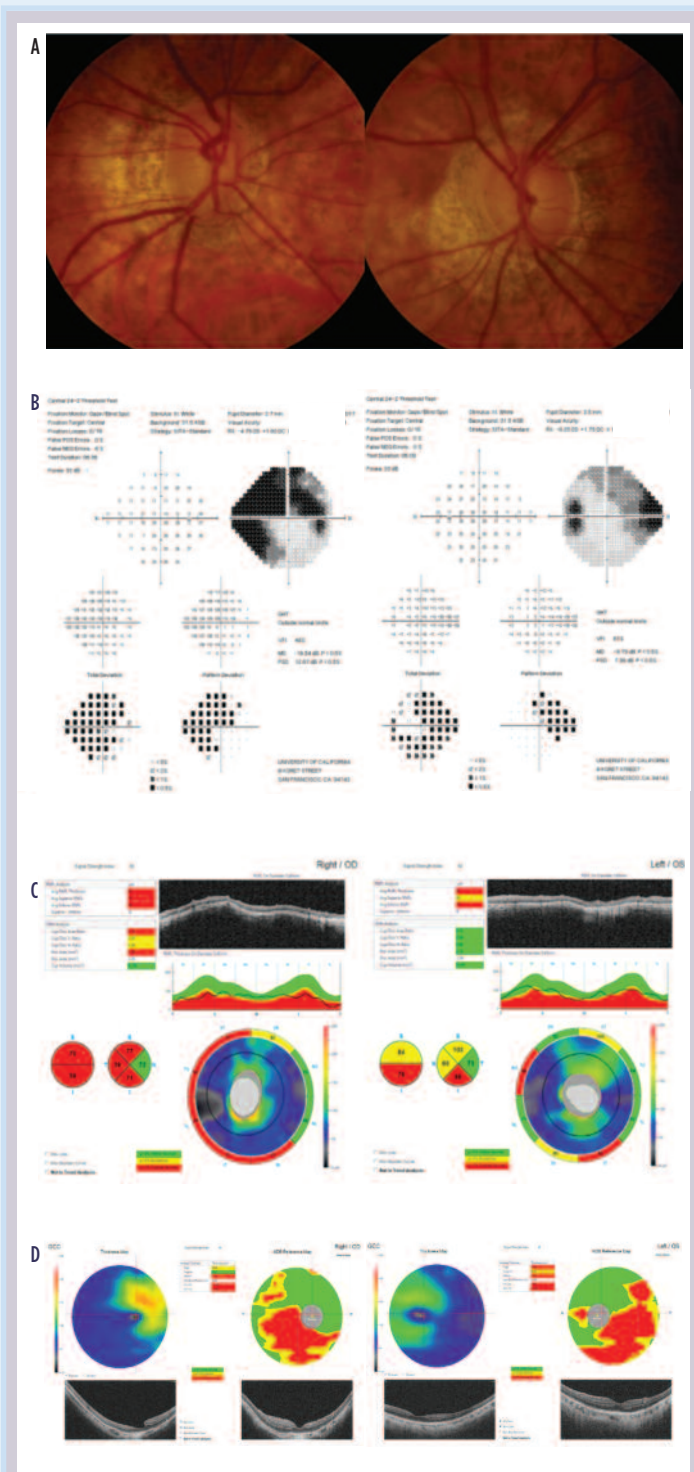


Figure 4. Clinical optic nerve photographs (A), visual fields (B), retinal nerve fiber layer optical coherence tomography images (C), and macular optical coherence tomography images (D) of the patient presented in Case 2

Images courtesy of Yvonne Ou, MD

trabeculectomy with mitomycin C, as performed in her right eye, but her ongoing CIN treatment puts her at increased risk for limbal stem cell failure, which glaucoma surgery might further exacerbate. A blebless minimally invasive glaucoma surgical procedure in combination with cataract surgery could be effective, but her cataract is actually more advanced in the right eye, so I would likely have to do cataract surgery there as well and this could jeopardize her new filtering bleb.

Dr Serle: In this case, given the complex issues around surgery, I might try SLT in hopes of getting a meaningful response despite the response in the fellow eye. What did you decide to do for her left eye?

Dr Ou: This all unfolded at precisely the time that latanoprostene bunod was approved. We were presented with an opportunity to try a new medication with a novel mechanism of action before proceeding to surgery. We replaced her current prostaglandin with latanoprostene bunod. Her IOP decreased from the 16 to 23 mm Hg range to the 14 to 17 mm Hg range.

Dr Serle: This is an important point. We want to switch from prostaglandins to latanoprostene bunod, not add, because latanoprostene bunod is metabolized to latanoprost plus NO. There is no additive value in double dosing prostaglandins, and there might be a downside; double dosing prostaglandins can actually raise IOP.^{37,38} Subsequently, netarsudil became available for clinical use, and it is another excellent option for this patient because of its novel mechanisms of IOP reduction and once-daily dosing regimen. Other attributes include additivity to prostaglandins and lack of systemic side effects.

Dr Goldberg: I have had a number of patients over the past few months who, like this patient, are on their maximal tolerated medical therapy, and in whom I am strongly considering surgical intervention. With the availability of 2 new therapies, I have discussed with patients deferring surgery, if only for a few months, if we could get better medical control of their IOP using either of these new agents. So over these past few months, I have strongly advocated testing the new therapies as an adjunct before subjecting a patient to trabeculectomy.

CASE 3

From the Files of Jeffrey L. Goldberg, MD, PhD

This is a 78-year-old male with normal-tension glaucoma. His maximum IOP has been 17 mm Hg OD and 18 mm Hg OS. His IOP is currently in the range of 11 to 12 mm Hg in both eyes following trabeculectomy in the left eye and a bilateral medical regimen of a prostaglandin, brimonidine, and the timolol/dorzolamide fixed combination. His right optic nerve has an inferior notch, whereas his left optic nerve is nearly cupped out. His right visual field is of limited reliability due to central macular geographic atrophy in that eye. In the left eye, the visual field has been reliable and has demonstrated reproducible progression of both superior and inferior fixation-threatening arcuate defects despite an IOP in the low teens. The RNFL OCT has also shown progression in the right eye, whereas the left eye has remained stable, possibly because of a floor effect, in which there is minimal residual structural loss to detect.

Dr Serle: Is there evidence that further IOP reduction is beneficial in eyes with such low starting IOPs?

Dr Ou: The Collaborative Normal-Tension Glaucoma Study demonstrated that a 30% IOP reduction significantly reduced the risk of progression in eyes with normal-tension glaucoma.³⁹ More recently, a study of eyes progressing with an IOP in the low teens demonstrated that surgical intervention to achieve single-digit target IOP stabilizes most eyes.⁴⁰

Dr Serle: The left eye is clearly progressing, with IOP in the low teens on maximal medical therapy, and has already failed one trabeculectomy. What is the next therapeutic step?

Dr Goldberg: The availability of drugs with novel mechanisms of action provides an opportunity to expand medical therapy while avoiding surgery or, in this case, reoperation. Either netarsudil or latanoprostene bunod might be a good choice for patients with low starting IOP. In the phase 3 ROCKET studies, netarsudil lowered IOP effectively across the spectrum of baseline IOP.²¹ Also, in a Japanese study of primarily patients with normal-tension glaucoma, latanoprostene bunod effectively lowered IOP, even in eyes with low baseline IOP.⁴¹ Other drugs, such as timolol and latanoprost, tend to be less effective as baseline IOP decreases.⁴² Perhaps drugs that work at the level of the trabecular outflow pathway are a good choice for eyes with low baseline IOP. In this case, the potential neuroprotective action of netarsudil that I described previously might provide an extra benefit for this patient.

Dr Herndon: We have to realize the limitations of medical therapy in patients such as this man with severe glaucomatous damage. I strive to achieve single-digit IOP goals in these patients, which can be achieved at the present time only through surgical means. If the previous trabeculectomy has some bleb elevation, then a bleb revision or a repeat trabeculectomy in the free superior quadrant could be considered.

Dr Ou: Surgery, such as bleb revision or a second trabeculectomy, might be a good option. I agree with Dr Goldberg, and would also consider adding netarsudil or switching to latanoprostene bunod. The former has the potential for conferring a neuroprotective effect. In the Low Pressure Glaucoma Treatment Study, patients treated with brimonidine were less likely to have visual field progression than patients treated with timolol, even though the mean IOP in both groups was similar, suggesting a neuroprotective effect.⁴³ I would be very interested in a clinical study using both structural and functional end points to examine the potential neuroprotective effect of netarsudil.

SUMMARY

Dr Serle: We now have 2 new IOP-lowering medications with novel mechanisms of action. Both latanoprostene bunod and netarsudil work in the TM to improve aqueous outflow, which is impaired in glaucoma. These new options expand our choices for medical therapy and permit us to develop treatment regimens that lower IOP through a variety of mechanisms.

Take-Home Points

- The primary cause of elevated IOP in glaucoma is impaired outflow of aqueous humor through the TM
- Two new drugs—latanoprostene bunod and netarsudil—lower IOP by increasing aqueous humor outflow through the trabecular outflow pathway
- These are the first drugs to directly improve trabecular outflow
- Both drugs offer the convenience of once-daily dosing
- Both drugs can be used as first-line or adjunctive therapy

ACKNOWLEDGMENTS

The faculty wish to acknowledge Tony Realini, MD, for medical writing assistance for this review.

REFERENCES

1. Grant WM. Experimental aqueous perfusion in enucleated human eyes. *Arch Ophthalmol*. 1963;69:783-801.
2. Grant WM. Clinical tonography. *Trans Am Acad Ophthalmol Otolaryngol*. 1951;55:774-781.
3. Park CY, Lee JK, Kahook MY, Schultz JS, Zhang C, Chuck RS. Revisiting ciliary muscle tendons and their connections with the trabecular meshwork by two photon excitation microscopic imaging. *Invest Ophthalmol Vis Sci*. 2016;57(3):1096-1105.
4. Stamer WD, Acott TS. Current understanding of conventional outflow dysfunction in glaucoma. *Curr Opin Ophthalmol*. 2013;23(2):135-143.
5. Liton PB, Gonzalez P, Epstein DL. The role of proteolytic cellular systems in trabecular meshwork homeostasis. *Exp Eye Res*. 2009;88(4):724-728.
6. Koener K, Zimmerman TJ, Fechtner RD. Section II: Glaucoma. In: Zimmerman TJ, Koone K, Sharir M, Fechtner RD, eds. *Textbook of Ocular Pharmacology*. 3rd ed. Philadelphia, PA: Lippincott Williams & Wilkins; 1997: 217-360.
7. Fraser TR. On the physiological action of the calabar bean. *J Anat Physiol*. 1867;1(2):323-332.
8. Cavet ME, Vollmer TR, Harrington KL, VanDerMeid K, Richardson ME. Regulation of endothelin-1-induced trabecular meshwork cell contractility by latanoprostene bunod. *Invest Ophthalmol Vis Sci*. 2015;56(6): 4108-4116.
9. Wang RF, Williamson JE, Kopczynski C, Serle JB. Effect of 0.04% AR-13324, a ROCK, and norepinephrine transporter inhibitor, on aqueous humor dynamics in normotensive monkey eyes. *J Glaucoma*. 2015;24(1):51-54.
10. Kazemi A, McLaren JW, Kopczynski CC, Heah TG, Novack GD, Sit AJ. The effects of netarsudil ophthalmic solution on aqueous humor dynamics in a randomized study in humans. *J Ocul Pharmacol Ther*. 2018;34(5):380-386.
11. Serle J. 3-month interim report of a prospective 12-month safety and efficacy study of topical PG324 (fixed combination of netarsudil 0.02% and latanoprost 0.005%) compared to the individual components in subjects with elevated intraocular pressure (MERCURY 1). Paper presented at: 2017 Annual Meeting of The Association for Research in Vision and Ophthalmology; May 7-11, 2017; Baltimore, MD; 2017.
12. VYZULTA [package insert]. Bridgewater, NJ: Bausch & Lomb Incorporated; 2017.
13. XALATAN [package insert]. New York, NY: Pfizer Inc; 2014.
14. Eveleth D, Starita C, Tressler C. A 4-week, dose-ranging study comparing the efficacy, safety and tolerability of latanoprost 75, 100 and 125 µg/mL to latanoprost 50 µg/mL (Xalatan) in the treatment of primary open-angle glaucoma and ocular hypertension. *BMC Ophthalmol*. 2012;12:9.
15. Cavet ME, DeCory HH. The role of nitric oxide in the intraocular pressure lowering efficacy of latanoprostene bunod: review of nonclinical studies. *J Ocul Pharmacol Ther*. 2018;34(1-2):52-60.
16. Wang J, Liu X, Zhong Y. Rho/Rho-associated kinase pathway in glaucoma (Review). *Int J Oncol*. 2013;43(5): 1357-1367.
17. Shaw PX, Sang A, Wang Y, et al. Topical administration of a Rock/Net inhibitor promotes retinal ganglion cell survival and axon regeneration after optic nerve injury. *Exp Eye Res*. 2017;158:33-42.
18. Ren R, Li G, Le TD, Kopczynski C, Stamer WD, Gong H. Netarsudil increases outflow facility in human eyes through multiple mechanisms. *Invest Ophthalmol Vis Sci*. 2016;57(14):6197-6209.
19. Holló G. The side effects of the prostaglandin analogues. *Expert Opin Drug Saf*. 2007;6(1):45-52.
20. Weinreb RN, Liebmann JM, Martin KR, Kaufman PL, Vittitow JL; ROCKET-1 and ROCKET-2 Study Groups. Latanoprostene bunod 0.024% in subjects with open-angle glaucoma or ocular hypertension: pooled phase 3 study findings. *J Glaucoma*. 2018;27(1):7-15.
21. Serle JB, Katz LJ, McLaurin E, et al; ROCKET-1 and ROCKET-2 Study Groups. Two phase 3 clinical trials comparing the safety and efficacy of netarsudil to timolol in patients with elevated intraocular pressure: Rho Kinase Elevated IOP Treatment Trial 1 and 2 (ROCKET-1 and ROCKET-2). *Am J Ophthalmol*. 2018;186:116-127.
22. US Food and Drug Administration. *Dermatologic and Ophthalmic Drugs Advisory Committee Meeting Briefing Document*. Silver Spring, MD: US Food and Drug Administration; October 13, 2017. NDA 208254.
23. Kim MJ, Park KH, Yoo BW, Jeoung JW, Kim HC, Kim DM. Comparison of macular GCIPL and peripapillary RNFL deviation maps for detection of glaucomatous eye with localized RNFL defect. *Acta Ophthalmol*. 2015;93(1):e22-e28.
24. Sung MS, Yoon JH, Park SW. Diagnostic validity of macular ganglion cell-inner plexiform layer thickness deviation map algorithm using cirrus HD-OCT in preperimetric and early glaucoma. *J Glaucoma*. 2014;23(8):e144-e151.
25. Nakatani Y, Higashide T, Ohkubo S, Takeda H, Sugiyama K. Evaluation of macular thickness and peripapillary retinal nerve fiber layer thickness for detection of early glaucoma using spectral domain optical coherence tomography. *J Glaucoma*. 2011;20(4):252-259.
26. Abitbol O, Bouden J, Doan S, Hoang-Xuan T, Gatinel D. Corneal hysteresis measured with the Ocular Response Analyzer in normal and glaucomatous eyes. *Acta Ophthalmol*. 2010;88(1):116-119.
27. Sullivan-Mee M, Billingsley SC, Patel AD, Halverson KD, Alldredge BR, Qualls C. Ocular Response Analyzer in subjects with and without glaucoma. *Optom Vis Sci*. 2008;85(6):463-470.
28. Congdon NG, Broman AT, Bandeen-Roche K, Grover D, Quigley HA. Central corneal thickness and corneal hysteresis associated with glaucoma damage. *Am J Ophthalmol*. 2006;141(5):868-875.
29. De Moraes CV, Hill V, Tello C, Liebmann JM, Ritch R. Lower corneal hysteresis is associated with more rapid glaucomatous visual field progression. *J Glaucoma*. 2012;21(4):209-213.
30. McClraith I, Strafeld M, Colev G, Hutnik CM. Selective laser trabeculoplasty as initial and adjunctive treatment for open-angle glaucoma. *J Glaucoma*. 2006;15(2):124-130.
31. Katz LJ, Steinmann WC, Kabir A, Molineaux J, Wizov SS, Marcellino G; SLT/Med Study Group. Selective laser trabeculoplasty versus medical therapy as initial treatment of glaucoma: a prospective, randomized trial. *J Glaucoma*. 2012;21(7):460-468.
32. De Keyser M, De Belder M, De Belder J, De Groot V. Selective laser trabeculoplasty as replacement therapy in medically controlled glaucoma patients [published online ahead of print June 21, 2017]. *Acta Ophthalmol*. doi:10.1111/aos.13509.
33. Francis BA, Ianchulev T, Schofield JK, Minckler DS. Selective laser trabeculoplasty as a replacement for medical therapy in open-angle glaucoma. *Am J Ophthalmol*. 2005;140(3):524-525.
34. Weinreb RN, Ong T, Scassellati Sforzolini B, Vittitow JL, Singh K, Kaufman PL; VOYAGER Study Group. A randomised, controlled comparison of latanoprostene bunod and latanoprost 0.005% in the treatment of ocular hypertension and open angle glaucoma: the VOYAGER study. *Br J Ophthalmol*. 2015;99(6):738-745.
35. Armstrong JJ, Wasiuta T, Kiatos E, Malvankar-Mehta M, Hutnik CML. The effects of phacoemulsification on intraocular pressure and topical medication use in patients with glaucoma: a systematic review and meta-analysis of 3-year data. *J Glaucoma*. 2017;26(6):511-522.
36. Shazly TA, Latina MA. Intraocular pressure response to selective laser trabeculoplasty in the first treated eye vs the fellow eye. *Arch Ophthalmol*. 2011;129(6):699-702.
37. Lindén C, Alm A. Latanoprost twice daily is less effective than once daily: indication of receptor subsensitivity? *Curr Eye Res*. 1998;17(6):567-572.
38. Herndon LW, Asrani SG, Williams GH, Challa P, Lee PP. Paradoxical intraocular pressure elevation after combined therapy with latanoprost and bimatoprost. *Arch Ophthalmol*. 2002;120(6):847-849.
39. Collaborative Normal-Tension Glaucoma Study Group. Comparison of glaucomatous progression between untreated patients with normal-tension glaucoma and patients with therapeutically reduced intraocular pressures. *Am J Ophthalmol*. 1998;126(4):487-497.
40. Iverson SM, Schultz SK, Shi W, Feuer WJ, Greenfield DS. Effectiveness of single-digit IOP targets on decreasing global and localized visual field progression after filtration surgery in eyes with progressive normal-tension glaucoma. *J Glaucoma*. 2016;25(5):408-414.
41. Kawase K, Vittitow JL, Weinreb RN, Araie M; JUPITER Study Group. Long-term safety and efficacy of latanoprostene bunod 0.024% in Japanese subjects with open-angle glaucoma or ocular hypertension: the JUPITER study. *Adv Ther*. 2016;33(9):1612-1627.
42. Bacharach J, Dubiner HB, Levy B, Kopczynski CC, Novack GD; AR-13324-CS202 Study Group. Double-masked, randomized, dose-response study of AR-13324 versus latanoprost in patients with elevated intraocular pressure. *Ophthalmology*. 2015;122(2):302-307.
43. Krupin T, Liebmann JM, Greenfield DS, Ritch R, Gardiner S; Low-Pressure Glaucoma Study Group. A randomized trial of brimonidine versus timolol in preserving visual function: results from the Low-Pressure Glaucoma Treatment Study. *Am J Ophthalmol*. 2011;151(4):671-681.



CME POST TEST QUESTIONS

To obtain *AMA PRA Category 1 Credit™* for this activity, complete the CME Post Test and course evaluation online at <https://tinyurl.com/newglaucomatx>. Upon successful completion of the post test and evaluation, you will be able to generate an instant certificate of credit.

See detailed instructions at **To Obtain AMA PRA Category 1 Credit™** on page 2.

- The primary source of aqueous outflow resistance in glaucomatous eyes is:
 - The uveoscleral outflow pathway
 - The cornea
 - The juxtacanalicular trabecular meshwork (TM)
 - Episcleral venous pressure
- In glaucomatous eyes, trabecular outflow is impaired because of:
 - Phospholipidosis in the TM
 - Impairment of metabolism in lysosomes
 - Oxidative stress and cellular debris in the trabecular cells
 - Deposition of prostaglandins in the extracellular matrix of the meshwork
- Beta blockers and carbonic anhydrase inhibitors lower IOP by:
 - Increasing uveoscleral outflow
 - Decreasing episcleral venous pressure
 - Increasing trabecular outflow
 - Decreasing aqueous humor production
- Prostaglandin analogues lower IOP by:
 - Increasing uveoscleral outflow
 - Decreasing episcleral venous pressure
 - Increasing trabecular outflow
 - Decreasing aqueous humor production
- Rho kinase inhibitors lower IOP primarily by:
 - Increasing uveoscleral outflow
 - Increasing episcleral venous pressure
 - Increasing trabecular outflow
 - Increasing aqueous humor production
- Netarsudil lowers IOP by approximately:
 - 1.5 to 3.0 mm Hg
 - 3.3 to 5.0 mm Hg
 - 4.5 to 7.0 mm Hg
 - 5.0 to 8.0 mm Hg
- Common side effects of netarsudil include:
 - Hyperemia, conjunctival hemorrhage, and corneal verticillata
 - Hyperemia, eye pain, and conjunctival hemorrhage
 - Eye pain, blurred vision, and corneal verticillata
 - Eye pain, hyperemia, and conjunctival hemorrhage
- Common side effects of latanoprostene bunod include:
 - Hyperemia and corneal verticillata
 - Eye pain and conjunctival hemorrhage
 - Eye pain and hyperemia
 - Hyperemia and blurred vision
- Which of the following is true regarding corneal verticillata?
 - It commonly causes reduced visual acuity
 - Netarsudil is the only drug associated with its formation
 - It has little or no effect on visual function in most affected patients
 - It is permanent and cannot be reversed by stopping the drug
- Both netarsudil and latanoprostene bunod are indicated for:
 - First-line therapy only
 - Adjunctive therapy only
 - When maximal medical therapy fails
 - The reduction of IOP in eyes with primary open-angle glaucoma or ocular hypertension